

Scar hypertrophy is reduced following topical treatment with amiloride: a preliminary finding in contact thermal injuries induced onto rabbit ears



A. Rodrigues, D. Dolivo, Y. Li, C. Hou, L. Sun, T. Mustoe, S. Hong, R. Galiano

Laboratory for Tissue Repair & Regenerative Surgery



INTRODUCTION

Worldwide burn prevalence and socioeconomic status are inversely proportional. Likewise, people suffer worse outcomes from thermal injuries in places where fewer medical resources exist. Budgets initiate this dilemma, and a lack of deterrents drive it. Despite well-established fire protective engineering and medical advancements, severe injuries recur worldwide, and survivors are often burdened with disfigured skin. Sequela such as hypertrophic scars, keloids and contractures frequently form after re-epithelialization, with all three manifestations harboring abundant extracellular fibrotic deposition, and often instigating pain, pruritus, paresthesia, limited mobility and mental illness.

Amiloride, an FDA-approved drug used to treat hypertension, heart failure and in some instances treat or prevent hypokalemia, functions through selectively inhibiting epithelial sodium channels (ENaC), Na⁺/H⁺ exchangers, and Na⁺/Ca²⁺ exchangers in kidney tubules, effectively reducing intracellular sodium and enhancing the tubule natriuretic effect. Amiloride also has activity outside of the kidney. In a previous study, we reported its ENaC antagonistic effect in human epidermal keratinocytes and found that agitation of ENaC-mediated sodium flux by dehydration activates fibroblasts through the cyclooxygenase-2/prostaglandin E2 (COX-2/PGE2) pathway, promoting collagen deposition. Given that burn injuries habitually dehydrate the wounds they comprise, we hypothesized that amiloride could reduce burn-induced hypertrophic scars by ultimately hindering the COX-2/PGE2 pathway.

METHODS

New Zealand White female rabbits aged between 17-22 weeks and weighing 2.7-3.2 Kg were utilized for this study. During discomforting procedure, animals were placed under an anesthetic plane with successive local and systemic pain control. Burns were performed with brass rods heated to 94°C and allowed to sit on the ventral ear for 8 seconds. Three 1-cm diameter burns were induced bilaterally onto each ear, and on POD 5,

debridement of eschar buildup was performed tangential to the underlying perichondrium with a 7 mm-diameter punch (Figure 2). Tegaderm film dressing was applied over the burns until complete re-epithelialization, and an Elizabethan collar was fastened to further safeguard the wounds. Immediately following wound re-epithelialization, the developing scars were topically treated with either amiloride or vehicle (transcutol [as a surfactant], capmul MCM [as an emulsifier] and vaseline), and at the conclusion of the study the healed wounds underwent scar elevation index (Figure 4) assessment along with qRT-PCR gene expression analysis for *PTGS2*, *ACTA2* and *COL1A1*.

RESULTS

Gross and histological results showed visible differences between amiloride and vehicle control treatment (Figure 3). SEI measurements demonstrated a significant reduction ($P < 0.05$) in scars treated with amiloride when compared to vehicle-treated scars (Figure 5A). Whole tissue qRT-PCR gene expression analysis for *PTGS2*, *ACTA2* and *COL1A1* resulted in no significant difference between scars treated with amiloride and those treated with vehicle control (Figure 5, B-D).

CONCLUSION

Topical application of amiloride after re-epithelialization reduces subsequent scarring in burn wounds, yet this finding necessitates further studies to comprehend the mechanism behind its therapeutic effect.

Figure 1: Timeline With Corresponding Events (POD = post operation day)

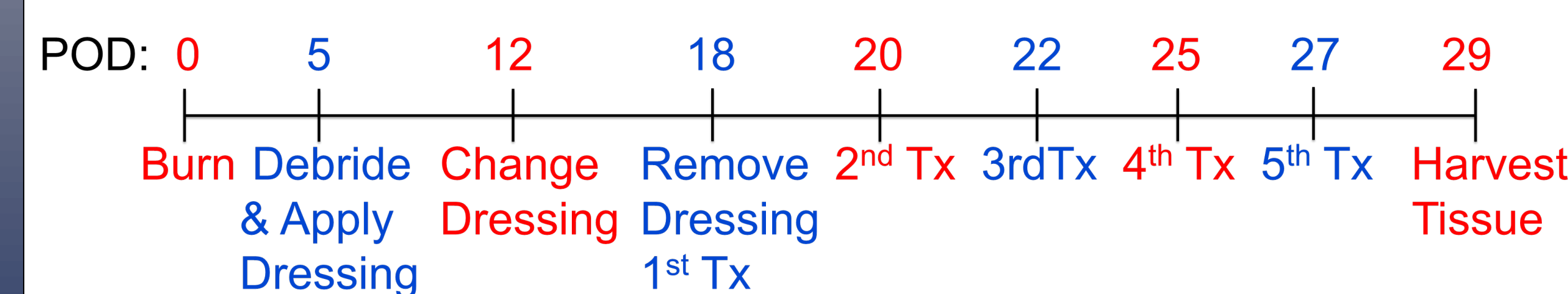


Figure 2: Burn Wound Progression

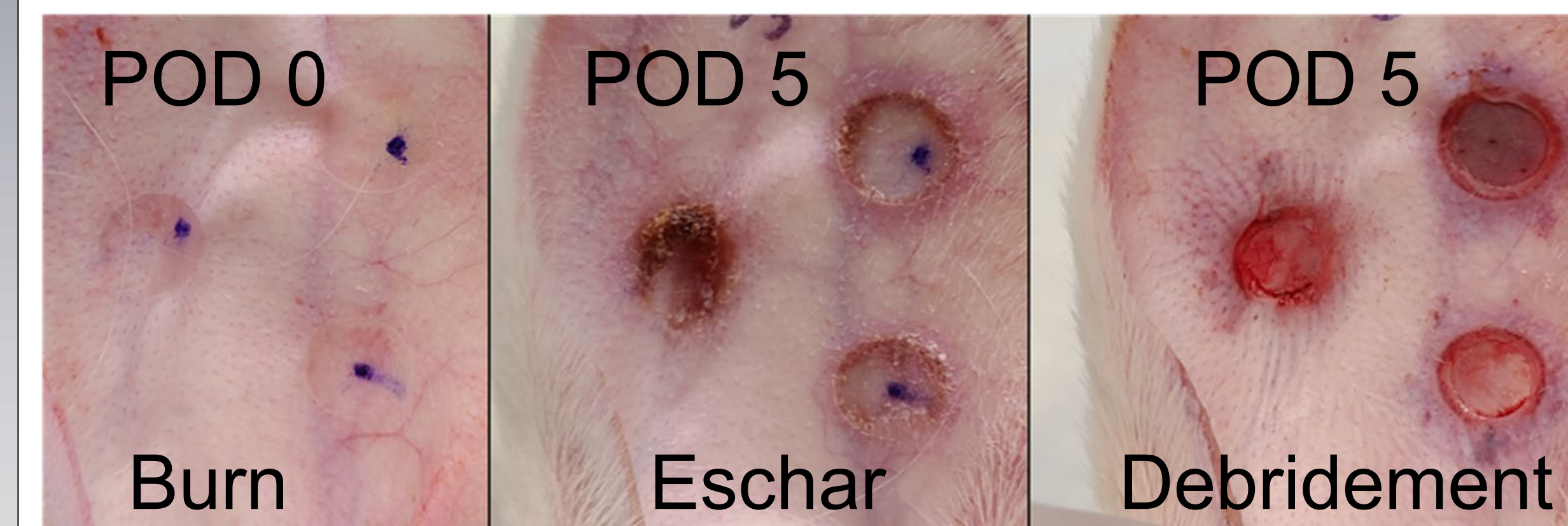


Figure 3: Gross & Histological Scars

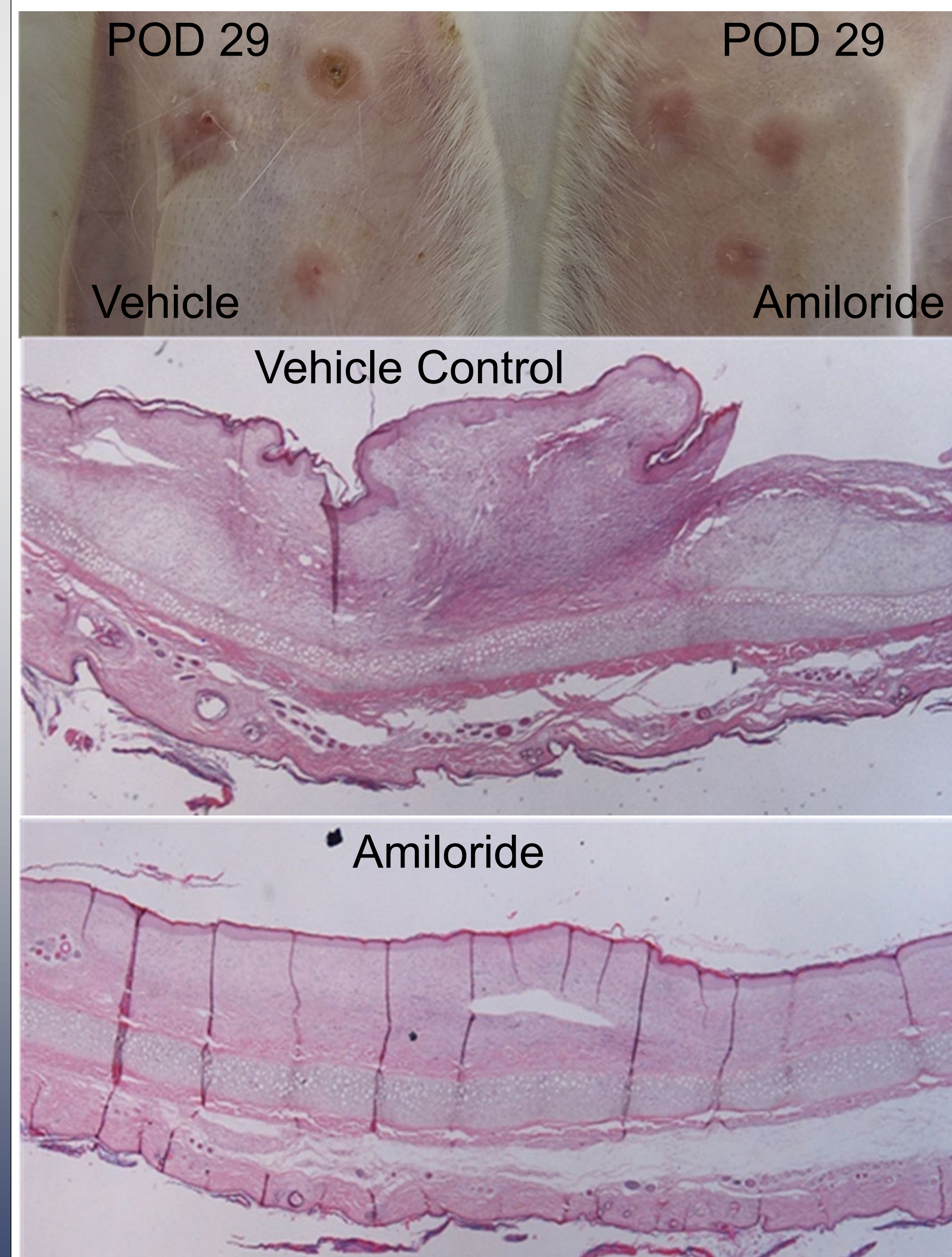


Figure 4: Sketch of Scar Elevation Index

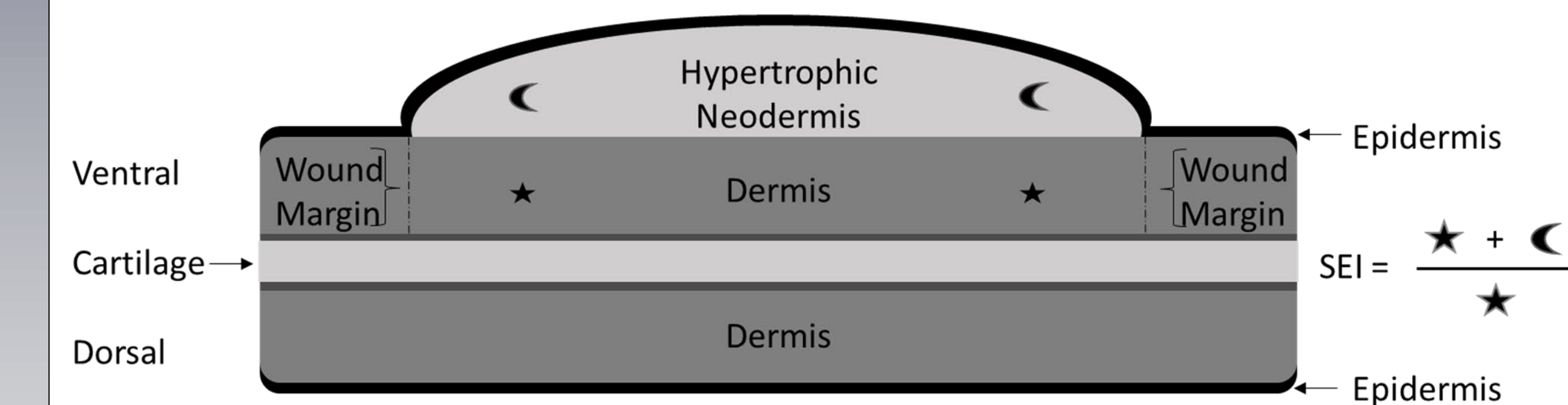


Figure 5: Graphical Data Results

